





Case Report.

Renal Fornix Rupture Due to Acute Ureteral Obstruction

João Marco Braz Scarpa Mariano Pereira¹ , Lucas de Souza Gomes¹, Leonardo de Oliveria Antunes¹ , Guilherme Diego de Oliveira Barbosa¹, José Vitor Santos Gomes¹ , Luiz Carlos Maciel¹ 

¹ University of Taubaté, Brazil.

* Correspondence: e-mail: joaomarcobraz@gmail.com

<https://doi.org/eiki/10.59652/aim.v2i2.209>

Abstract: Background: Renal fornix rupture with fluid extravasation is a rare complication in cases of ureteral obstruction, which is usually caused by obstructive ureterolithiasis. The symptoms of renal fornix rupture are not very specific and can easily go unnoticed due to their underlying cause.

Case representation: The present article reports a case of a patient of a 70-year-old, male, who was diagnosed with a ruptured renal fornix due to acute ureteral obstruction, following clinical assessment and a non-contrast CT scan. The proposed course of action was the endoscopic placement of a double J ureteral catheter.

Conclusion: In the case described, the conservative treatment that was chosen by passing a double J catheter through the left ureter, for the patient proved to be an alternative to surgical treatment in the acute event, reducing the risk of possible complications from the operation. It was possible to conclude that although renal fornix rupture is a rare emergency with multiple etiologies, conservative treatment with urinary diversion using a double J ureteral stent was effective in solving the patient's acute condition.

Keywords: fornix rupture, ureterolithiasis, double J catheter, ureteral obstruction, clinical assessment

1. Introduction

Rupture of renal fornix with fluid extravasation is a rare complication in cases of ureteral obstruction, which is usually caused due to an obstructive, and therefore acute, ureterolithiasis. This condition may also be related to other pathologies, such as genitourinary tract neoplasms, the presence of a posterior urethral valve, the existence of retroperitoneal fibrosis, pregnancy, due to a large increase in intra-abdominal pressure (1, 2, 3, 4, 5) and benign prostatic hyperplasia, with few reports described (2).

The symptoms of renal fornix rupture are not very specific and can easily be disguised by its underlying cause, which usually presents as ureterolithiasis, i.e., it can present severe pain in the flank of the injured organ associated with nausea and vomiting (1,4,5). When its underlying cause is related to an infravesical obstruction, it can present with edema, leukocytosis, and even a bexigoma (2).

Its diagnosis can be made by associating the clinical examination with imaging tests, such as: excretory urography (1), USG, CT, which can identify perirenal fluid extravasation. In addition, it is important to emphasize that US is the test of choice in pregnant women due to the lack of exposure to radiation (1, 3, 4).

Emergency therapy for cases of fornix rupture due to ureterolithiasis consists of the passage of a double J catheter into the ureter of the injured kidney associated with antibiotic

Received: 24/05/2024

Accepted: 31/05/2024

Published: 01/06/2024



Copyright: © 2024 by the authors.

Submitted for open access publication under the terms and conditions of the Creative Commons Attribution (CC BY) license

(<https://creativecommons.org/licenses/by/4.0/>).

therapy, due to the infectious risk (1,2,3,4). In addition, other guidelines report that a tube can be placed for percutaneous nephrostomy to decompress the injured site (4).

Based on this theme, the aim of this study is to highlight the relevance of the occurrence of a rare condition in urology, the fornix rupture and the type of treatment performed (conservative - passage of double J catheter) as an alternative to surgical treatment.

2. Materials and Methods

The database used to describe this report were: the analysis of medical records, evolution, laboratory tests and imaging tests carried out, which were applied to determine the respective diagnosis of the patient in question. In addition, previous studies of renal fornix rupture were used as a bibliographic reference, which were available in PubMed and Scielo.

3. Case Report

Patient D.G.B., male, 70 years old, was admitted to the emergency room with severe pain in the left flank, starting 7 hours ago. Associated with nausea and vomiting, he denied fever or other symptoms.

Past pathological history: coronary heart disease.

Commonly used medications: rosuvastatin and aspirin.

Allergies: denied.

Physical examination: Regular general condition, lucid and oriented in time and space, flushed, hydrated, anicteric, acyanotic and afebrile

Heart system: Regular rhythm in 2 beats, normal sounds, no audible murmurs

Respiratory system: breath sounds present, no adventitious sounds

Abdomen: flaccid and painful on palpation of the left flank.

Extremity: Peripheral pulses present and symmetrical, without cyanosis or edema

Laboratory tests: Hemoglobin: 14.9; Hematocrit: 43.9; Leukocytes: 10900 (neutrophils 87.9%, rods 2%); platelets 259,000; Creatinine: 0.75; Urea: 42; PCR: 0.5

Imaging test: (Image 1 and 2)

CT scan of the abdomen showed probable rupture of the fornix with the presence of perirenal fluid around the left kidney. No other changes.

Diagnostic hypothesis: The patient was admitted to hospital and instructed about the possible diagnosis of ureterolithiasis with probable fornix rupture and indication of double J catheter passage.

Evolution: In the operating room, a cystoscopy was performed with the passage of a double J catheter on the left, a procedure performed without intercurrents, in the post-operative period the patient presented slightly hematuric diuresis after passage of an indwelling urinary catheter, denying nausea, vomiting and other symptoms. Ceftriaxone was administered in-hospital for 2 days and at hospital discharge, cefuroxime was prescribed for 7 days and hydration. The patient was instructed to return for the removal of a double J catheter and for ultrasound of the kidneys and urinary tract to confirm the reabsorption of the perirenal fluid present around the left kidney.

On the return visit, ultrasound of the kidneys and urinary tract showed no abnormalities. The removal of the double J catheter was scheduled. The patient had a good clinical evolution after the procedure.

Figure 1

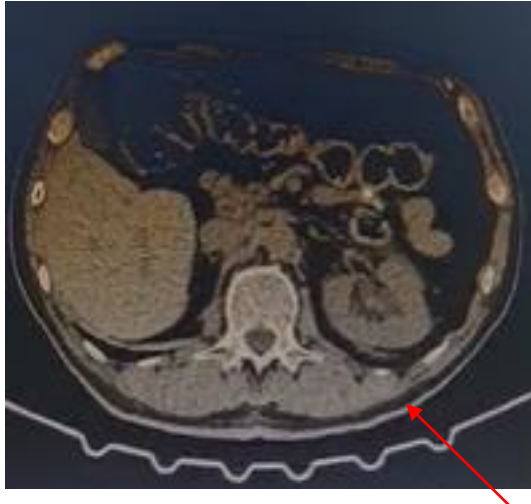


Figure 2.

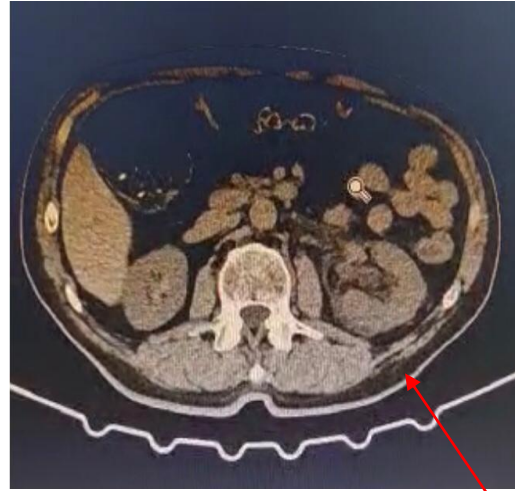


Figure 1 and 2: The arrow shows the renal fornix rupture.

4. Discussion

Rupture of renal fornix with fluid extravasation is a rare case within the urological entity, and may or may not be of traumatic origin (3). According to a study produced by Ercil et al., in 43 patients diagnosed with fornix rupture, 77.4% were caused due to pre-existing renal lithiasis, in 4 different cases (9.3%) there was no underlying diagnostic cause for this outcome (3, 6 and 7). The obstruction, associated with the increase in the intraluminal pressure of the ureter, can cause the rupture of the collecting system and consequently, a mechanism explained by Laplace's law, the tensile stress transmitted through a dilated collecting system increases with size, thus causing fornix rupture in a more dilated system, an increase in pressure that exceeds the tensile strength of the fornix tissues leads to interruption and extravasation of urine. (5,8). Such as what occurred in the present case report.

The clinical picture presented may be variable, such as the presence of pain in the flank of the injured kidney, nausea, vomiting, or even characterized as an acute abdomen. Therefore, clinical presentations such as pyelonephritis, appendicitis, duodenal ulcer and symptomatic cholelithiasis can be identified based on these symptoms, in addition to being differential diagnoses in this case(7).

From the point of view of diagnostic imaging, ultrasonography can identify hydronephrosis, the presence of collections, or the presence of stones. However, the reference test is a computed tomography scan with delayed time acquisition, which can accurately show the contrast extravasation and the exact site of the rupture (8,9). The most common form, approximately 75% of cases, is distal rupture, due to the majority of stones being located below the sacroiliac vessels (i.e., distal ureter and UVJ) and distal stones were significantly smaller than the proximal stones observed by the systematic review of 108 cases by Gershman B. et al (10).

The emergency treatment described in the literature consists of a urinary diversion by double ureteral stent J or percutaneous nephrostomy, with the treatment of the underlying cause, which should be performed after resolution of the acute episode, as was done in the case described in this article(3,8,11). If left untreated, this formed urinoma can lead to the

formation of perirenal abscess, sepsis, retroperitoneal fibrosis, loss of function, and even death, with the prognosis varying according to the patient's underlying pathologies, renal injury, rupture site, and presence of infection (3,10 and 11). Thus, justifying the use of antibiotic therapy in the postoperative period, which evolved favorably.

5. Conclusions

Renal fornix rupture is a rare emergency of multiple etiologies. In this way, studies that lead to the detailing of patients affected by this disease in other institutions can contribute to a positive evolution in the quality of hospital care. In addition, it can be concluded that conservative treatment with urinary bypass in a double ureteral J stent is effective and has good results.

Moreover, due to the fact that there are few cases reported and discussed in the literature, it can be concluded that this study was extremely important, as it could help, in different way, future conduct when urologists are faced with rare case of renal fornix rupture.

References

1. Cabral, E. B., de Almeida, J. L., GUIMARÃES, E. V., & DA PAIXÃO, A. M. L. (2022). Renal fornix rupture with formation of urinanium. *Caminhos da Clínica*, 1(01).
2. Larrache, Y., et al. Spontaneous renal fornical rupture due to a bladder tumor. *Urology Case Reports.*, v. 33, p. 101340, 1 nov. 2020.
3. Nedjim SA, Abdi M, Al Afifi M, Hagguir H, Mahanna HA, Nachid A, Moataz A, Dakir M, Debbagh A, Aboutaieb R. Spontaneous rupture of the fornix due to a ureteral lithiasis of 3 mm causing a urinoma: report of an original case. *Radiol Case Rep.* 2021 Aug 5; 16(10):3143-3146. doi: 10.1016/j.radcr.2021.06.065. PMID: 34484508; PMCID: PMC8403901.
4. Grossmann, N. C., Ardizzone, D., Hermanns, T., Keller, E. X., & Fankhauser, C. D. (2023). Is conservative management safe in patients with acute ureterolithiasis and perirenal stranding?. *Urolithiasis*, 51(1), 40.
5. Spinelli, M. G., Palmisano, F., Zanetti, S. P., Boeri, L., Gadda, F., Talso, M., ... & Montanari, E. (2019). Spontaneous upper urinary tract rupture caused by ureteric stones: A prospective high-volume single centre observational study and proposed management. *Arch. Esp. Urol*, 72(6), 6.
6. Pampana, E., Altobelli, S., Morini, M., Ricci, A., d'Onofrio, S., & Simonetti, G. (2013). Spontaneous ureteral rupture diagnosis and treatment. *Case reports in radiology*, 2013.
7. ERCIL Hakan, TÜMER Erbay, SENTÜRK Aykut Bugra ~, et al. Etiology and treatment of renal fornical rupture: a single center experience. *J Urol Surg.* 2018; 5(2):68.
8. Al-Mujalhem AG, Aziz MS, Sultan MF, Al-Maghraby AM, MA Al-Shazly. Spontaneous fornical rupture: can it be treated conservatively? *Urol Ann.* 2017; 9:41-4.
9. Gershman B, Kulkarni N, Sahani DV, Eisner BH. Causes of renal fornical rupture. *BJU Int.* 2011 Dec; 108(11):1909-11; discussion 1912. doi: 10.1111/j.1464-410X.2011.10164.x. Epub 2011 Jul 8. PMID: 21736690.
10. Coelho RF, Schneider-Monteiro ED, Mesquita JL, Mazzucchi E, Marmo Lucon A, Srougi M. Renal and perinephric abscesses: analysis of 65 consecutive cases. *World J Surg.* 2007; 31:431-6.
11. Balsells FS, De Torres Mateos JA, Mas AG, Lopes FG. Physiopathology of spontaneous extravasation of urine in the upper urinary tract. Apropos of 24 cases. *J Urol Nephrol* 1976; 82:385-95 (Paris).